

Comentario a la nota clínica: Esofagitis necrotizante aguda en paciente inestable

Comment on the clinical note: Acute necrotizing esophagitis in an unstable patient

V.M. Santos^{1,2}, R.B. Villaça³, I.P. Gouvêa⁴, D.A.R. Sá²

Rodrigo M et al described a case of black esophagus (BE) in a 77-year-old male who developed severe hemodynamic instability, and BE was cited as rare condition¹. The mentioned report is very interesting and well documented, but additional comments and illustrations from the study of a Brazilian patient with coexistent BE and candidiasis could be appropriate to emphasize concerns about frequency rate and associated factors.

Although ischemic factors can play a pathogenic role, hemodynamically stable patients have presented with BE too. Worth of note, only about a hundred cases of this entity were reported since the first description in 1990¹⁻⁴; notwithstanding, published necropsy data are suggestive that BE may be under diagnosed and/or under reported^{2,5}. The aim of the present paper is to enhance the suspicion index about BE, which will have better outcome if early diagnosis and precocious treatment can be accomplished.

An 83-year-old male was admitted because of hypoglycemia, vomiting, dysphagia, and weight loss. He was in use of NPH insulin and furosemide to treat diabetes and

hypertension and there was antecedent of an advanced invasive rectal cancer. The endoscopy study detected mild stricture, ulceration and black discoloration in distal esophagus (Fig. 1A), in addition to duodenal ulcers. Esophageal biopsy samples showed characteristic features of acute esophageal necrosis and ulcerated esophagitis (Fig. 1C), coexistent with local accentuated moniliasis (Fig. 1D). Rectosigmoidoscopy revealed an ulcerated infiltrative rectal tumor at 3cm from the anal limit, affecting $\frac{3}{4}$ of the lumen. The diagnosis of rectal carcinoma was confirmed by biopsy (Fig. 1D). TC showed perirectal invasion and liver implants. Remarkable laboratory data were hypoalbuminemia, accentuated anemia and leukocytosis with neutrophilia, in addition to hyponatremia and high platelet count¹⁻⁴. These changes can be found in acute phase response (APR) and protein-energy malnutrition (PEM)^{6,7}. He received gastric protection, total parenteral nutrition and intravenous fluconazole. Even with clinical improvement, the patient refused treatment for advanced cancer. After gastrostomy done because of esophageal stenosis, he was referred to home-care support.

An. Sist. Sanit. Navar. 2009; 32 (3): 439-442

1. Catholic University Medical Course.
2. Department of Internal Medicine from Armed Forces Hospital (HFA). Estrada do Contorno do Bosque s/n, 70.603-900. Brasília-DF. Brazil.
3. Department of Gastroenterology from HFA.
4. Department of Pathology from HFA.

Correspondencia

Vitorino Modesto dos Santos
SMPW Quadra 14, Conjunto 2, Lote 7, Casa A
Setor de Mansoes Park Way, 71745-140
Brasília-DF. Brazil
Tfno. (0xx55) 61 33802666
Fax (0xx55) 61 32331599
E-mail: vitorinomodesto@gmail.com

In spite of the malignant co morbidity and indicative features of APR and PEM, there was no circulatory instability, and the clinical evolution was favorable. Wallberg et al. reported similar favorable outcome of BE in a 75-year patient with sepsis⁴, which is a major cause of systemic inflammatory response and circulatory failure. Common clinical features are dyspepsia, epigastralgia, hematemesis, melena, and vomiting, but the diagnosis suspicion of BE during endoscopy must be further confirmed by histological data. Circumferential black discoloration is often seen in distal esophagus, with mucosa erosions, ulcers, exudates, necrosis and vessel thrombi¹⁻⁴. Differential diagnosis of

BE includes acanthosis nigricans, melanoma, melanosis, pseudomelanosis, ocnosis and necrotic lesions due to caustic or corrosive agents¹⁻⁴.

Risk factors for BE include alcoholism, cardio circulatory disorders, pulmonary diseases, cirrhosis, diabetes, esophagitis, gastric obstruction, hiatal hernia, malignancies, malnutrition, and renal failure¹⁻⁴. Interestingly, esophageal candidiasis or rectal cancer are associations very rarely reported. Malignancies found in patients with BE are: cancers from colon, biliary tract, hypofarynx, lung, ovary, pancreas, prostate, and rbdomyosarcoma. Esophageal stricture is the major complication^{2,4}.

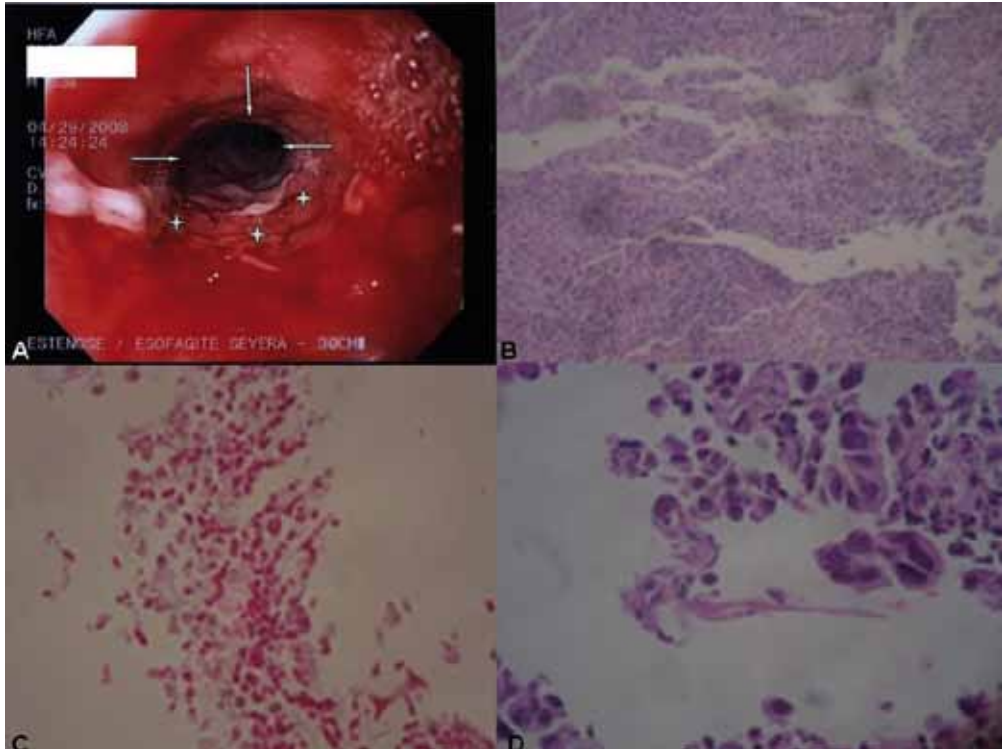


Figure 1A. Accentuated acute esophagitis, with fibrinous exudates, enanthema, edema and friable mucosa (stars); in addition to stenosis and circumferential black discoloration in the distal portion of esophagus (arrows).

Figure 1B. Acute necrotizing esophagitis, showing fibrin and necrotic material in the ulcerated lesion. Necrotic changes were limited to mucosa and submucosa (HE 100x).

Figure 1C. Esophageal candidiasis characterized by numerous spores of *Candida sp* (HE PAS 600x).

Figure 1D. Cells of the rectal infiltrative carcinoma showing cytoplasmic vacuolization (HE 600x).

Coexistent BE and candidiasis should be better cleared because: reports about this association are rare^{5,8,9}; endoscopy disclose esophageal candidiasis in 1-8% of all patients examined¹⁰; fungi may be opportunistic agents in immunocompromised individuals⁸⁻¹⁰, including those with APR and

PEM associated with cancer or AIDS^{5,8,9}. As occurred in the present case, the esophageal changes may undergo favorable resolution after management with proton pump inhibitors, sucralfate, and nutrition care, in addition to treatment of associated infections (Table 1).

Table 1. Comparative data from five patients with black esophagus associated with esophagitis by fungi.

Authors/ year	Patients	Main risk factors	Fungal agents associated with black esophagus	Fluconazole	Outcome
Hoffman et al, 1999	30y, male	AIDS	<i>Penicillium chrysogenum</i>	No (Ket + Nys)	†
Ben Soussan, 2002	68y, male	Prostate cancer	«Minor mycotic infection»	No	†
Ferreira et al, 2007	52y, male	Rabdomyosarcoma	<i>Candida albicans</i> , <i>Aspergillus</i> , and <i>Actinomyces</i>	Yes	†
Kim and Choi, 2007	34y, male	Ketoacidosis, DM	<i>Candida</i>	Yes	Favorable
Santos et al, 2009	83y, male	Rectal cancer, DM	<i>Candida sp</i>	Yes	Favorable

DM: diabetes mellitus; Ket: ketoconazole; Nys: nystatin; †: death.

As necropsy data have suggested that BE can be under diagnosed, case reports and letters to the editor could increase the awareness about this disorder.

REFERENCES

- RODRIGO M, GORRAIZ BE, MERINO C, EGUARAS J, ELIZALDE JM, SOLER W. Esófagitis necrotizante aguda en paciente inestable. *An Sist Sanit Navar* 2009; 32: 113-116.
- JULIÁN GÓMEZ L, BARRIO J, ATIENZA R, FERNÁNDEZ-ORCAJO P, MATA L, SARACÍBAR E et al. Acute esophageal necrosis. An underdiagnosed disease. *Rev Esp Enferm Dig* 2008; 100: 701-705.
- RAMOS R, MASCARENHAS J, DUARTE P, VICENTE C, CASTELEIRO C. Acute esophageal necrosis: a retrospective case series. *Rev Esp Enferm Dig* 2008; 100: 583-585.
- WALLBERG ME, YOUNG P, FINN BC, THOMÉ M, CHUECO AA, VILLAREJO F. Esófago negro secundario a esofagitis necrotizante aguda. Reporte de un caso clínico. *Rev Méd Chile* 2009; 137: 672-674.
- BEN SOUSSAN F, SAVOYE G, HOCHAIN P, HERVÉ S, ANTONIETTI M, LEMOINE F et al. Acute esophageal necrosis: a 1-year prospective study. *Gastrointest Endosc* 2002; 56: 213-217.
- MONTEIRO JP, CUNHA DF, DA CUNHA SF, DOS SANTOS VM, SILVA-VERGARA ML, CORREIA D et al. Resposta de fase aguda, subnutrição e estado nutricional do ferro em adultos com AIDS. *Rev Soc Bras Med Trop* 2000; 33: 175-180.
- SANTOS VM, CUNHA SF, CUNHA DF. Velocidade de sedimentação das hemácias: utilidade e limitações. *Rev Assoc Med Brasil* 2000; 46:232-236.
- FERREIRA S, CLARO L, SOUSA R, VITORINO E, LAGE P, CHAVES P et al. Esófago negro associado a infecção por *Candida albicans*, *Aspergillus* e *Actinomyces*. *J Port Gastroenterol* 2007; 14: 143-146.
- HOFFMAN M, BASH E, BERGER AS, BURKE M, YUST I. Fatal necrotizing esophagitis due to *Penicillium chrysogenum* in a patient with acquired immunodeficiency syndrome. *Eur J Clin Microbiol Infect Dis* 1992, 11: 1158-1160.
- KIM YH, CHOI SH. Black esophagus with concomitant candidiasis developed after diabetic ketoacidosis. *World J Gastroenterol* 2007; 13: 5662-5663.

RÉPLICA DEL AUTOR

Agradecemos el interés mostrado por V.M. Santos, R.B. Villaça, I.P. Gouvêa y D.A.R. Sá a nuestra comunicación sobre esofagitis necrotizante aguda (ENA) o esófago negro. El interesante caso clínico que presentan ilustra otra de las situaciones asociadas con esta entidad, en este caso candidiasis; nosotros ya indicamos su posible asociación con infección esofágica.

Ciertamente, pacientes circulatoriamente estables pueden presentar ENA. Sin embargo, y a partir de los datos aportados en su comunicación, queda en nuestra opinión una duda razonable de si el caso presentado se corresponde exactamente con una situación de estabilidad. Los autores refieren ausencia de inestabilidad circulatoria, pero entre la información referida a

su admisión no constan tensión arterial, frecuencia cardíaca, valoración de la perfusión distal y de la hidratación, coloración cutánea, transpiración y otros signos exploratorios que ayudan a definir una situación de inestabilidad hemodinámica. El paciente presentaba disfagia, malnutrición energético-proteica, vómitos en cuantía y duración no concretadas y tratamiento con furosemida. Todo lo cual puede generar una situación, si no de inestabilidad hemodinámica, al menos de hipovolemia, que podría condicionar, a su vez, hipoperfusión esofágica y, en consecuencia, ENA.

Finalmente, los autores afirman que el esófago negro tendrá mejor resultado con un diagnóstico y tratamiento precoces. Lo cual, en ausencia de pruebas o referencias que apoyen su afirmación, entendemos que es una opinión personal.